

Teeth Through the Ages

Six Months:

All the immature incisors are still present. Usually there are only four cheek teeth showing with the third premolar having three cusps. See **Fig. 1**.

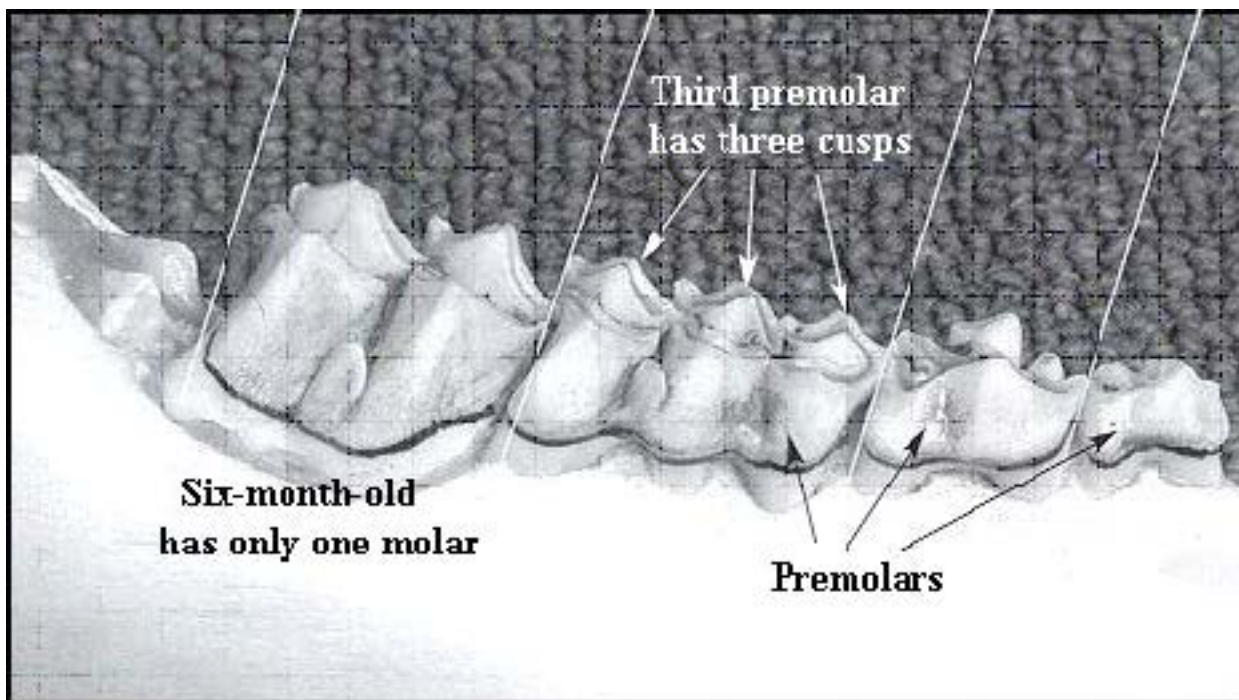


Fig. 1

1½Years:

All permanent front teeth are in place. Six cheek teeth are visible in the lower jaw. The third premolar may still have three cusps and be well worn. The third molar has started to break through the gum and shows no sign of wear. Lingual crests of molars have sharp points. See **Fig. 2**.

The Science Behind Algonquin's Animals

WWW.SBAA.CA

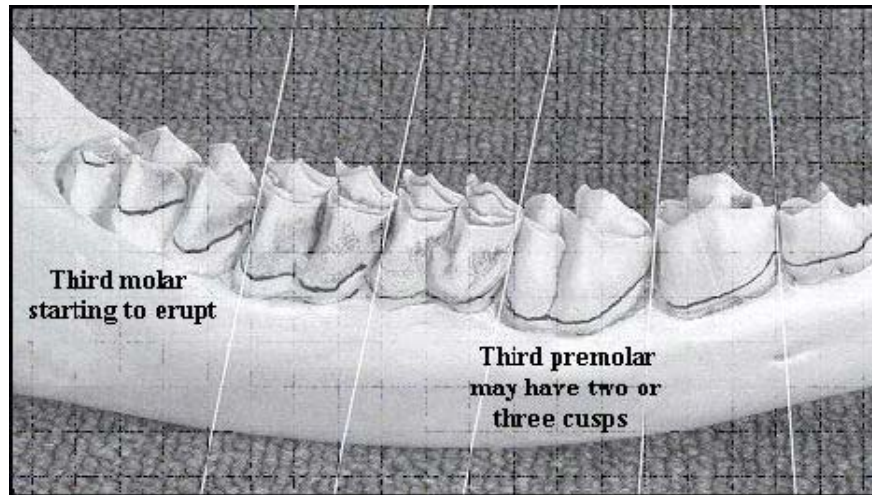


Fig. 2

2½ Years:

All the premolars and molars are in and show slight wear and are stained. See Fig. 3.

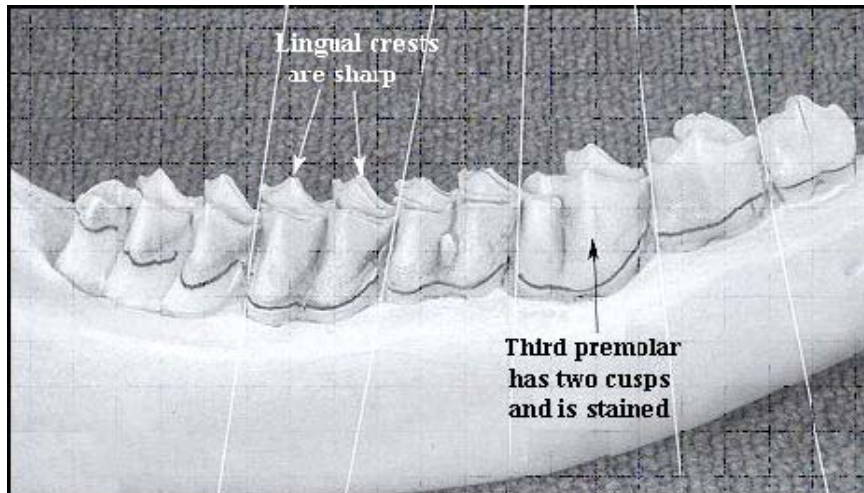


Fig.3



ONTARIO
PARKS



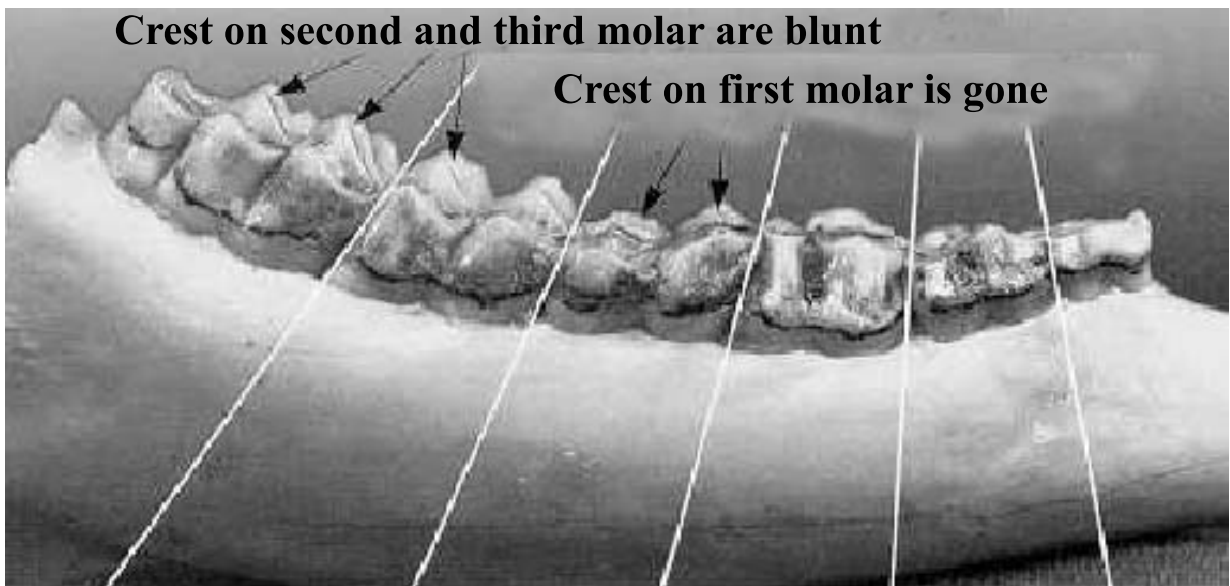
Ontario

The Science Behind Algonquin's Animals

WWW.SBAA.CA

4½ Years and Older:

Aging Moose and deer 4½ to 8½ years is difficult. Wear on the lingual crest and cupping of molars becomes increased and pronounced. By 8½ years the pit, or infundibula of the first molar (fourth cheek tooth) will be completely worn away and animals older than 8½ years show excessive wear and cupping in all molars. By 12½ years the infundibula of the third premolar is usually worn away completely. See **Fig. 4 to 6**.



The Science Behind Algonquin's Animals

WWW.SBAA.CA

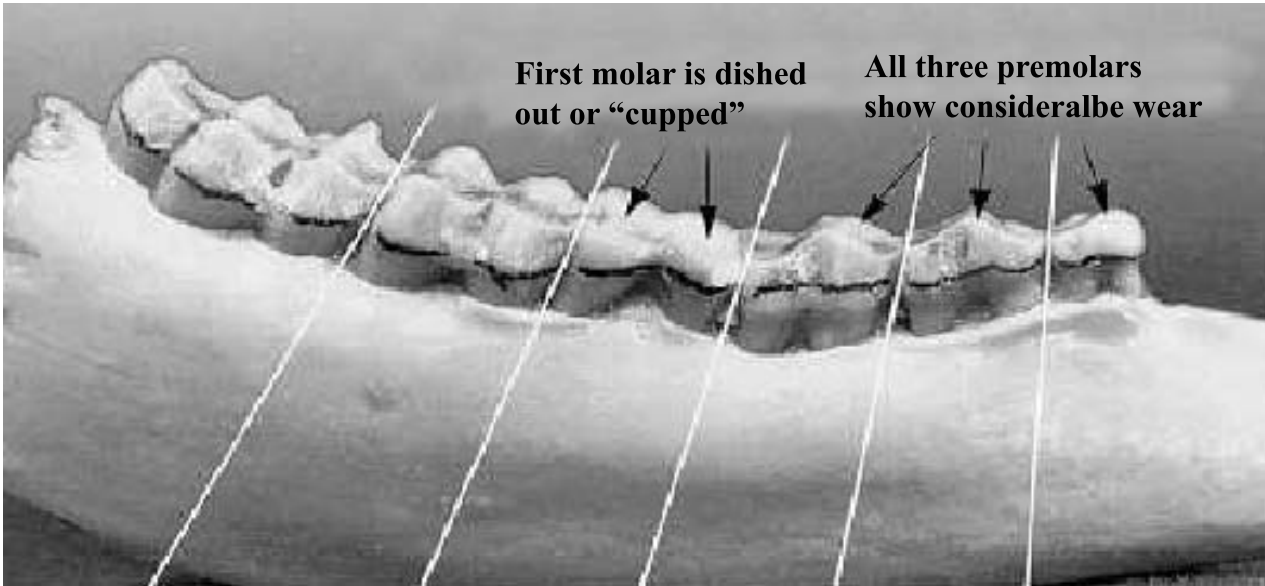


Fig. 5 5 1/2 Years

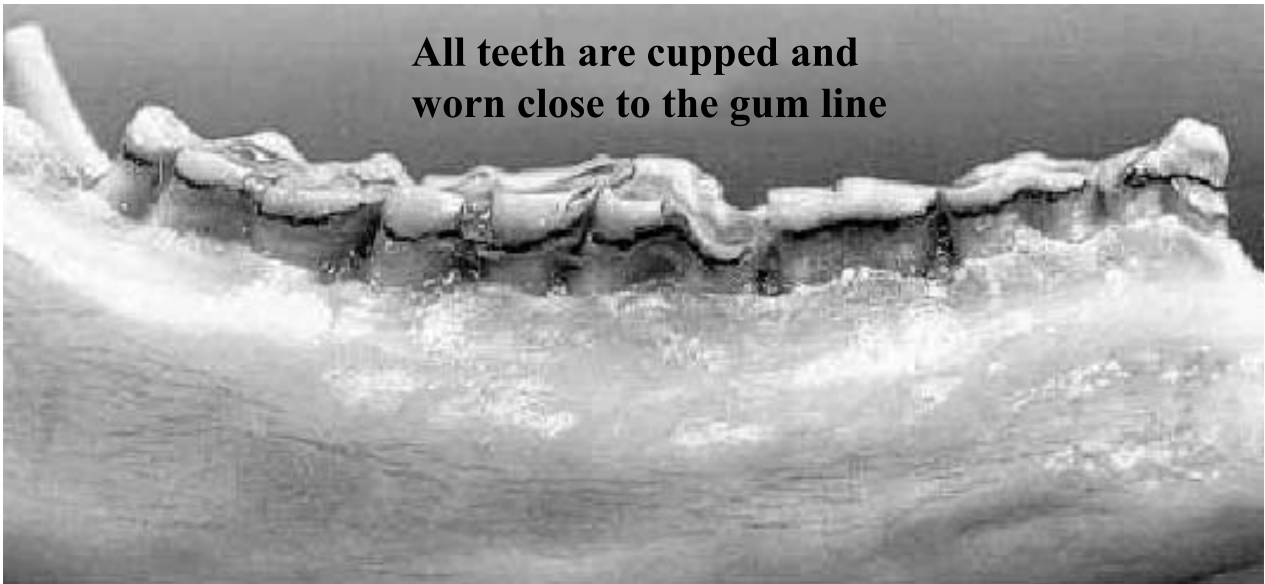


Fig. 6 9 1/2 Years